

Clinical Utilization of OxyBand

Applications Protocols & Indications

Description: OxyBand is an advanced technology that provides for the transdermal delivery of 100% oxygen to both acute wounds and chronic ulcers*. The device delivers oxygen continuously via sustained release over an extended period of time, to 5 days as long as OxyBand remains intact and secure around the perimeter. At 5 days OxyBand has been shown in a bench test to still have 65% oxygen. Air is 21% oxygen. OxyBand has been shown in case studies by independent, physicians to be used over 7 days (see Appendix A, Niezgodá et. al). OxyBand should be changed accordingly

The number of days between OxyBand changes depends upon the size and metabolic characteristics of the ulcer. OxyBand can be applied as either a primary dressing, or it can be utilized with other primary dressings (alginate, foam, collagen, hydrofiber, hydrocolloid, etc.) and in this application serve as the secondary dressing.

Indications: As all chronic ulcers with compromised or delayed healing are thought to be hypoxic, OxyBand is indicated and cleared for use in Pressure Ulcers, Venous Insufficiency Ulcers, Arterial Ulcers, Mixed Vascular Ulcers, and Diabetic Ulcers. Compromised acute surgical wounds such as dehisced surgical wounds, compromised skin flaps and grafts, traumatic wounds and burns are also additional indications for the use of OxyBand. Application of transdermal oxygen as a postoperative dressing can also be beneficial by mitigating potential post-operative complications.

Application Guidelines: The following information is intended to serve as a guideline for the application of OxyBand to a wound or ulcer. As with any technology of device the technology must be utilized and customized as needed to match the needs of the individual patient as well as to best accommodate the unique characteristics of the wound.

1. Standard Basic wound care must be deployed when using OxyBand.
 - Debridement: If indicated wounds with necrotic tissue, fibrin or slough should be debrided, to provide for a clean wound base.
 - Bioburden, Biofilm and Infection: Careful consideration of bacterial contamination and colonization should be accomplished and suspected biofilm or bacterial colonization addressed. The clinical diagnosis of wound infection must be treated and managed.
 - Tissue Compromise by External Forces: Efforts to evaluate and mitigate external forces that may be compromising healing must be accomplished. Pressure ulcers need aggressive pressure redistribution protocols and the reduction of shear and friction**. Diabetic foot ulcers must be appropriately offloaded.
 - Moisture Balance: Consideration and management of wound moisture is critical. When wound surfaces are dry, the addition of moisture is indicated. Wounds

with excessive exudate are at risk for moisture associated dermatitis and compromise. Efforts to decrease, or absorb excessive wound exudate is prudent.

- Vascular Interrogation and Intervention: All patients must be screened for both arterial and venous insufficiency. Patients with suspected arterial disease must receive Ankle Brachial Index testing or formal Duplex assessment. Patients with suspected venous insufficiency must receive Duplex evaluation for reflux and valvular incompetency. Patients with significant vascular disease mandate referral via vascular consultation.
 - Nutritional Evaluation: All patients with healing compromise should receive nutritional screening for protein energy malnutrition or nutritional compromise. Those patients identified as at nutritional risk require management with dietary intervention.
2. The wound is cleansed and prepared in the standard clinical fashion.
 3. An appropriate topical dressing is applied to the wound surface as indicated based on the individual patient and wound characteristics.
 4. While not mandatory, the periwound may be prepped using skin protectant. Benzoin or Cyanoacrylate may be applied to the periwound if the patient requires enhanced adherence to create an airtight seal when applying OxyBand.
 5. OxyBand is removed from the supplied packaging.
 6. The device is prepared for application by removing the protective film from the wound side of the OxyBand, exposing the adherent surface of the device, allowing for flow of the oxygen thru the circular pores in the membrane into the wound base.
 7. The device is then applied over the wound with the pores facing the wound base.
 8. The 4 ½ by 5 ½" OxyBand is packaged with a foam and a perforated hydrocolloid. The hydrocolloid or the foam can be used underneath the OxyBand over the wound or the OxyBand, can be applied over the hydrocolloid with the foam applied over the wound.
 9. The margins are then secured to the tissue around the wound base as smoothly as possible. Working the border in a circular fashion is often helpful. Extra attention to this step is critical so as to avoid areas of tenting or nonadherence so as to prevent leaks. To perform optimally OxyBand requires an air-tight seal to the external environment.
 10. The control strip on the border of the external surface that allows for ease in handling the device is then gently removed, with caution not to pull the adhesive undersurface of the device away from contact with the periwound skin. Extra tape or adherent film can be used to additionally secure the margins along the device border if needed.
 11. No additional dressing is required over OxyBand; however, the following clinical information and guidance is provided:
 - OxyBand can be used under compression wraps.
 - OxyBand can be used in conjunction with Total Contact Casting.

- OxyBand should be more carefully secured when utilized on wound located in areas of movement and motion (i.e., over joints)
- OxyBand can be safely used during Hyperbaric Oxygen Therapy
- OxyBand can be applied over all CTPs

OxyBand provides sustained oxygen delivery to wounds over days. A study has shown that upon attaching OxyBand over a test plate, oxygen levels rise steadily over the device area for the first few hours and then maintain at elevated levels through 5 days as long as the OxyBand remains intact and secure around the perimeter. At 5 days OxyBand was shown to still have 65% oxygen. Air is 21% oxygen. OxyBand has been shown in case studies by independent, physicians to be used over 7 days (see Appendix A, Niezgoda et. al). OxyBand should be changed accordingly

The following are Special Considerations:

- More frequent changes may be indicated for wounds with high metabolic demands, such as the infected wound.
- OxyBand should also be changed when wound exudate has exceeded the capacity and the absorptive properties of the primary dressing. Fluid and excessive exudate should not be allowed to accumulate or pool inside the device.
- OxyBand should be removed if a patient begins to demonstrate erythema that was not present prior to the application.
- If OxyBand is applied over a wound with some erythema noted in the periwound tissues, the extent of the baseline erythema should be recorded and monitored. OxyBand should be removed if the erythema begins to extend more than 1 cm beyond the documented margins.
- OxyBand should be removed if hemorrhage or purulence is noted inside the device.

*For simplification wound will be used to describe both wounds and ulcers for the remainder of this document.

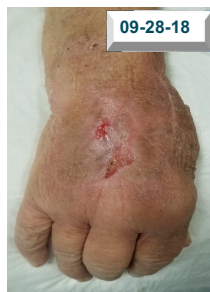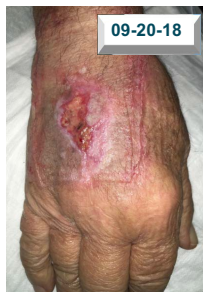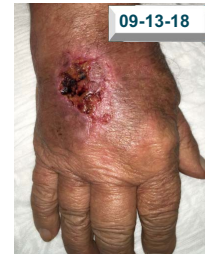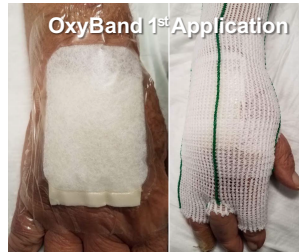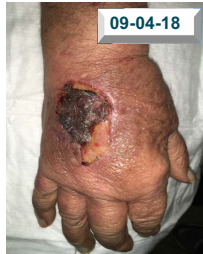****OxyBand has been proven to be superior to all other dressings (based pressure mapping with decreased peak and average pressures and increased surface area of distribution) currently marketed for use in patients with pressure ulcers with the additional claim of enhanced pressure redistribution. OxyBand should be considered for use in patients with all stages of pressure ulcer and can also be considered for use for pressure prevention. (Unique Properties of Oxygenated Composite Dressing Provides Superior Pressure Redistribution. JA Niezgoda, JA Niezgoda – Presented at the 2018 APWCA National Meeting, Baltimore, MD

Appendix A: Case Study Exam

Transdermal Oxygen in Management of Compromised Skin Flap

Jeffrey A. Niezgoda, MD

FACHM, MAPWCA, CHWS



OxyBand provides transdermal oxygen for recovery of tissue compromised by hypoxia – which in this case prevented loss of the flap.

OxyBand was applied every 7 days, extended wear time.

1 OxyBand vs. 3 to 4 SOC dressings/week

- Well tolerated by patient

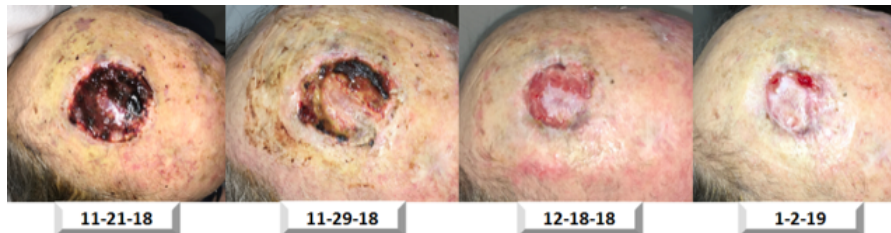
Appendix A: Example of Case Studies/Slide 1

Radiated Cancer Site with Failed Skin Graft

Jeffrey A. Niezgoda MD

FACHM, MAPWCA, CHWS

Radiated Cancer site that was unhealed and infected for over 1 year. 1st photo is before OxyBand and last photo is after 4 weeks of OxyBand applied every 7 days.



Appendix A: Example of Case Studies/Slide 2